



OPEN ACCESS

Largest size of extra-abdominal fibromatosis of axilla in a young man

Anil Kumar,¹ Subhash Kumar,² Ruchi Sinha,³ Veena Kumari⁴

¹General Surgery (Trauma), All India Institute of Medical Sciences, Patna, India

²Radiodiagnosis, All India Institute of Medical Sciences, Patna, India

³Pathology, All India Institute of Medical Sciences, Patna, India

⁴Burn and Plastic, All India Institute of Medical Sciences, Patna, India

Correspondence to

Dr Anil Kumar,
dranil4@gmail.com

Accepted 14 July 2019

DESCRIPTION

An 18-year-old man presented with complaint of large size lump of 22×18×10 cm in the left axilla for >4 years duration. He also had complaint of restricted movement of left upper limb at shoulder joint. His upper limb was always in the abducted position for last 9 months because of large size of lump in his left axilla (figure 1). The patient had no history of constitutional symptoms including weight loss, loss of appetite, fever, cough or respiratory problem. He had no history of surgery or trauma in axillary or thorax region. On physical examination, in the left axilla, a hard, firm and fixed mass of size 22×18×10 cm was palpable. The lump was non-tender on palpation with irregular margin. There was no impulse on coughing and lump was non-reducible. All laboratory tests were within normal limits. Fine needle aspiration cytology was done two times with non-conclusive result. Patient underwent for surgical exploration under general anaesthesia. Intraoperatively the adherent mass was extended up to subclavian vessels, scapular area and chest wall up to nipple with irregular margin and fibrous consistency (figure 2A,B). The tumour was large in size, gray-white in colour, fibrotic in consistency with irregular margin. The axillary vessels and other accompanying vessels were intact. Total excision of the tumour including intercostal muscles and perichondral tissues were carried out. Pathological examination confirmed the diagnosis of extra-abdominal fibromatosis (EAF). EAF is also known as aggressive fibromatosis (or desmoid tumour).¹ EAF

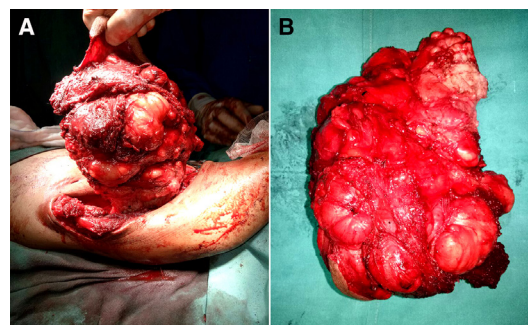


Figure 2 (A) The tumour invading up to the scapula and intercostal muscles. (B) The excised tumour measured 22×18×10 cm in size.

constitutes <0.03% of all neoplasm and one-third of all desmoid tumours.² The most common site for EAF is shoulder and upper limb (33%) followed by lower limb (30%), chest (18%) and head and neck (10%).³ Although MRI is the imaging modality of choice but diagnosis is confirmed histologically with the evidence of abundant collagen mixed with spindle cells, fibroblasts with abundant eosinophilic cytoplasm.^{3,4} The radical surgical excision at earliest is the best treatment modality and avoid the need of chemotherapy, radiotherapy or hormonal therapy to prevent recurrence.^{5,6} The axillary fibromatosis is rarely reported in literature and size of 22×18×10 cm is extremely rare.⁷ On reviewing all the literatures, the largest size of EAF which was 21 cm in size located over chest wall was reported by Agarwal *et al*.⁸ The EAF of axilla with largest size were 4×4×3 and 10×8×5 cm³ reported by Pacheco Compañía *et al* and Duan *et al*, respectively.^{5,9} In the series by Kabir *et al* and Zehani-Kassar *et al*, the average size of tumour was 6 and

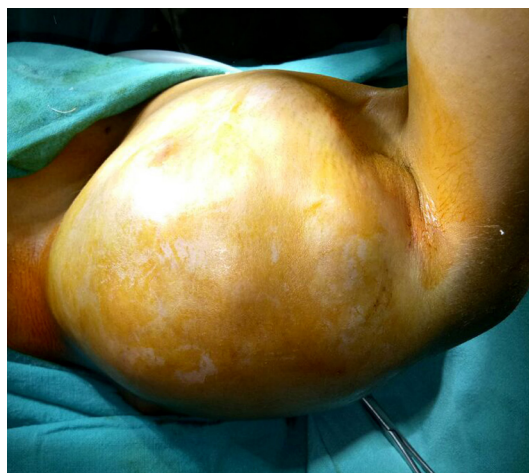

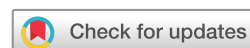Figure 1 Showing axillary lump of 22×18×10 cm in size.

Patient's perspective

I am very thankful to operating team.

Learning points

- ▶ Extra-abdominal fibromatosis (EAF) of axilla is extremely rare.
- ▶ Even the largest size of EAF of axillary region can be excised without damaging to the axillary vessels and in advanced stage reconstruction with vascular graft may be considered.
- ▶ Chemotherapy is very effective to prevent its postoperative recurrence.



© BMJ Publishing Group Limited 2019. Re-use permitted under CC BY-NC. No commercial re-use. See rights and permissions. Published by BMJ.

To cite: Kumar A, Kumar S, Sinha R, *et al*. *BMJ Case Rep* 2019;**12**:e230670. doi:10.1136/bcr-2019-230670

8.75 cm, respectively.^{10 11} In other two reports by Ali Kaygin *et al* and Jain *et al* described the EAF of popliteal region with size of 9 and 8 cm, respectively.^{12 13} We aim to report this case since to the best of our knowledge this case presents the largest size of EAF in a male patient.

Acknowledgements The corresponding author would like to thanks to Dr Nishant Sahay, Dr Sanjeev Kumar and Mr Amit Kumar Singh for their help in writing this manuscript.

Contributors AK: operated this case and wrote the manuscript. SK: did CT and MRI. RS: concept of article and HPE. VK: review the whole manuscript.

Funding The authors have not declared a specific grant for this research from any funding agency in the public, commercial or not-for-profit sectors.

Competing interests None declared.

Patient consent for publication Obtained.

Provenance and peer review Not commissioned; externally peer reviewed.

Open access This is an open access article distributed in accordance with the Creative Commons Attribution Non Commercial (CC BY-NC 4.0) license, which permits others to distribute, remix, adapt, build upon this work non-commercially, and license their derivative works on different terms, provided the original work is properly cited and the use is non-commercial. See: <http://creativecommons.org/licenses/by-nc/4.0/>

REFERENCES

- 1 Delloye C, Viejo-Fuertes D, Scalliet P. Treatment of aggressive fibromatosis: a multidisciplinary approach. *Acta Orthop Belg* 2004;70:199–203.

- 2 Escobar C, Munker R, Thomas JO, *et al*. Update on desmoid tumors. *Ann Oncol* 2012;23:562–9.
- 3 Shinagare AB, Ramaiya NH, Jagannathan JP, *et al*. A to Z of desmoid tumors. *AJR Am J Roentgenol* 2011;197:W1008–W1014.
- 4 Ibrahim M, Sandogji H, Allam A. Huge intrathoracic desmoid tumor. *Ann Thorac Med* 2009;4:146–8.
- 5 Pacheco Compañia FJ, Alvarez Jorge A, Delgado Sotorrio C. Extra-abdominal desmoid tumor located in the axilla. *Arch Plast Surg* 2014;41:780–2.
- 6 Lee SH, Lee HK, Song JS, *et al*. Chest wall fibromatosis in the axilla. *Arch Plast Surg* 2012;39:175–7.
- 7 Allen PJ, Shriver CD. Desmoid tumors of the chest wall. *Semin Thorac Cardiovasc Surg* 1999;11:264–9.
- 8 Agrawal R, Choudhary P, Goel AK, *et al*. Large chest wall fibromatosis with challenging treatment plan. *J Cancer Metastasis Treat* 2017;3:139–43.
- 9 Duan M, Xing H, Wang K, *et al*. A large and aggressive fibromatosis in the axilla: a rare case report and review of the literature. *Oncotargets Ther* 2018;11:3179–84.
- 10 Kabiri EH, Al Aziz S, El Maslout A, *et al*. Desmoid tumors of the chest wall. *Eur J Cardiothorac Surg* 2001;19:580–3.
- 11 Zehani-Kassar A, Ayadi-Kaddour A, Marghli A, *et al*. Desmoid-type chest wall fibromatosis. A six cases series. *Orthop Traumatol Surg Res* 2011;97:102–7.
- 12 Ali Kaygin M, Dag O, Erkut B, *et al*. Extra-abdominal fibromatosis (desmoid tumor): a rare tumor of the lower extremity arising from the popliteal fossa. *Case Rep Vasc Med* 2011;2011.
- 13 Jain M, Das SS, Gantaguru A, *et al*. A rare case of extra-abdominal desmoid-type fibromatosis arising from the popliteal fossa. *Cureus* 2018;10:e3651.

Copyright 2019 BMJ Publishing Group. All rights reserved. For permission to reuse any of this content visit <https://www.bmj.com/company/products-services/rights-and-licensing/permissions/>
BMJ Case Report Fellows may re-use this article for personal use and teaching without any further permission.

Become a Fellow of BMJ Case Reports today and you can:

- ▶ Submit as many cases as you like
- ▶ Enjoy fast sympathetic peer review and rapid publication of accepted articles
- ▶ Access all the published articles
- ▶ Re-use any of the published material for personal use and teaching without further permission

Customer Service

If you have any further queries about your subscription, please contact our customer services team on +44 (0) 207111 1105 or via email at support@bmj.com.

Visit casereports.bmj.com for more articles like this and to become a Fellow