



OPEN ACCESS

Urinary tract obstruction in the second trimester: a report of an incarcerated gravid uterus

Mariana Morais , Mário Moura, Ana Correia, Yida Fan

Obstetrics and Gynecology,
Centro Hospitalar de Trás-os-
montes e Alto Douro EPE, Vila
Real, Portugal

Correspondence to

Dr Mariana Morais;
mariana.lira.morais@gmail.com

Accepted 15 September 2022

SUMMARY

Incarceration of the gravid uterus (IGU) is a rare obstetric disorder that may lead to pregnancy-related complications. Acute urinary retention (AUR) is one of the associated symptoms in IGU and it is mostly observed in the first semester and early second trimester. A case of a woman, in her 30s, is described, who presented AUR and lower abdominal pain in the early second trimester. The diagnosis was confirmed upon pelvic examination, and abdominal and transvaginal ultrasound. Management included long-term bladder catheterisation, manual reduction manoeuvres and passive positioning manoeuvres at home. At 24 weeks of gestation, the uterus returned in its correct polarity, the Foley catheter was removed and the patient was able to void spontaneously. A healthy infant was delivered vaginally at term. No specific guidelines have been published for IGU treatment. However, prompt diagnosis and tight follow-up of these patients are essential to define strategies, reduce complications and prevent recurrences.

BACKGROUND

Uterine retroversion is presented in approximately 11%–15% of pregnancies during the first trimester.^{1–5} In most cases, retroversion can spontaneously turn into an axial position throughout pregnancy, especially after the 14th week, when the gravid uterus expands into the abdominal cavity.⁴

On rare occasions, the uterus remains in a retroverted position and becomes trapped inside the pelvis between the sacral promontory and the symphysis pubis.^{3 4 6–8} This obstetric condition is referred to as incarcerated gravid uterus (IGU), which is an uncommon situation, occurring in about 1 in 3000–10 000 pregnancies.^{2 7–9} IGU typically occurs by 14–16 weeks of gestational age and a few cases maintain IGU in the third trimester.⁸

Some of the risk factors described for the occurrence of IGU are uterine anomalies, endometriosis, uterine prolapse, fibroids, pelvic adhesions or a deep sacral cavity with a prominent promontory. Nevertheless, IGU can also happen in the absence of predisposing factors.^{1 4 7 10}

Patients most commonly present lower abdominal and pelvic pain, constipation and urinary symptoms such as frequent urination, dysuria, urinary retention or overflow incontinence.⁴ Vaginal bleeding is uncommon in these patients.⁸

Acute urinary retention (AUR) secondary to IGU is a rare emergency during pregnancy and it can lead to maternal and fetal complications. This condition is mostly observed between the 9th and

16th week.^{5 10} Adverse outcomes associated with IGU and AUR are renal failure, bladder or uterine rupture, hydronephrosis, urinary tract infection, premature rupture of membranes, preterm delivery, fetal growth restriction and miscarriage.^{4 11} Identification of clinical signs and imaging features are essential in determining to an early diagnosis for adequate treatment/management proper a management in order to reverse the situation and avoid such complications.

There are no specific guidelines for optimal management, due to its rarity, and its approach during pregnancy is currently based on case reports.^{4 9}

Here, we present a IGU case with AUR which emphasises the need to early recognition and prompt management of the condition during pregnancy.

CASE PRESENTATION

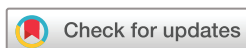The patient was a pregnant woman in the early second trimester having had two previous vaginal deliveries and no relevant medical record. The combined screening test for aneuploidies revealed an increased risk for Down syndrome (1:37) therefore, an invasive technique was performed. The cytogenetic analysis revealed a normal karyotype (46,XX).

The patient the emergency service with lower abdominal pain and AUR at 14 weeks+4 days of gestation. No vaginal bleeding or obstipation was mentioned.

Pelvic examination revealed an acute anterior angulation of the vagina, a stage 1 apical prolapse with the external cervical os palpable very anteriorly and a urethral prolapse in the lower third of the urethra. Uterine fundus was not palpable during abdominal examination. Transvaginal ultrasound was performed and revealed a long cervix positioned behind symphysis pubis. The anterior angulation of urethra and vagina was confirmed in the pelvic floor assessment by a two-dimensional introital ultrasound. This angulation might contribute to an abnormal urinary flow and culminate in AUR (see figure 1).

Abdominal ultrasound showed a retroverted uterus with the uterine fundus bending to the posterior fornix, the cervix pushed anteriorly and an elongated and compressed bladder (see figures 2 and 3).

A viable intrauterine pregnancy with adequate biometric measurements for gestational age was confirmed.



© BMJ Publishing Group Limited 2022. Re-use permitted under CC BY-NC. No commercial re-use. See rights and permissions. Published by BMJ.

To cite: Morais M, Moura M, Correia A, et al. *BMJ Case Rep* 2022;**15**:e249986. doi:10.1136/bcr-2022-249986

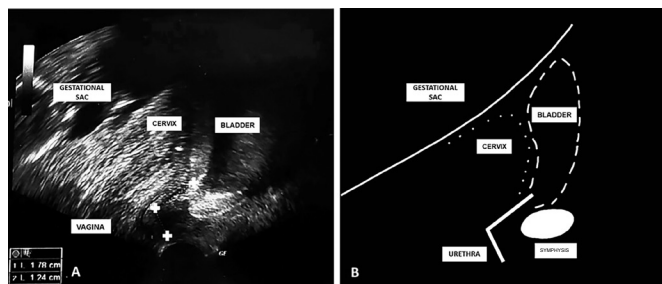


Figure 1 (A) Pelvic floor assessment by a two-dimensional introital ultrasound of a 16-week pregnancy in an incarcerated uterus with acute urinary retention. The urethra presented with an anterior acute angulation (crosses). The cervix and the gestational sac were represented. (B) Illustration showing anatomical relationships between the cervix (dotted lines), bladder (dashed lines), urethra and bone markers.

Routine urinalysis, urine culture and renal function laboratory tests were normal.

The diagnosis of IGU was assumed, based on all the findings.

Urine drainage with catheter was immediately performed to relieve the symptoms. The patient was discharged after voiding spontaneously.

The patient returned to the hospital, with the same symptoms, forty hours later. After bladder catheterisation, manual reduction manoeuvres in dorsal lithotomy position with manipulation of the uterine fundus through the posterior vaginal fornix were unsuccessfully attempted. The patient did not mention any discomfort during these manoeuvres and fetal well-being was ensured at the end of the procedure. Despite the persistent retroverted position, the patient was able to spontaneously void and was discharged.

TREATMENT

Frequent urinary retention episodes due to IGU continued. Management included long-duration urinary catheterisation and urinary tract infection prophylaxis with nitrofurantoin. The patient was advised to adopt a knee-chest prone position for 10–15 min at least three times a day. The uterus position and possible fetal complications were assessed by follow-up ultrasounds.

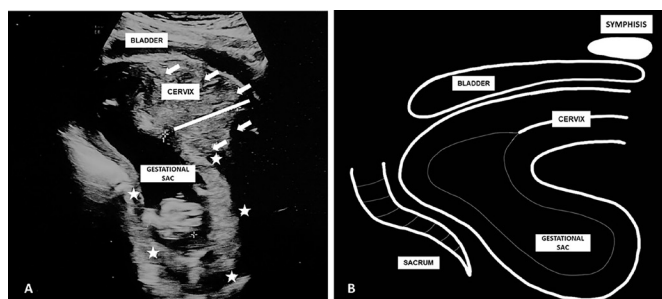


Figure 2 (A) Transabdominal ultrasound of a 16-week pregnancy in an incarcerated uterus. Cervix (arrows) was anterior and behind the symphysis. Bladder was elongated and compressed. The fundus of the uterus (stars) was posterior and caudal to the cervix. (B) Illustration showing anatomical relationships between the incarcerated uterus, bladder and bone markers.

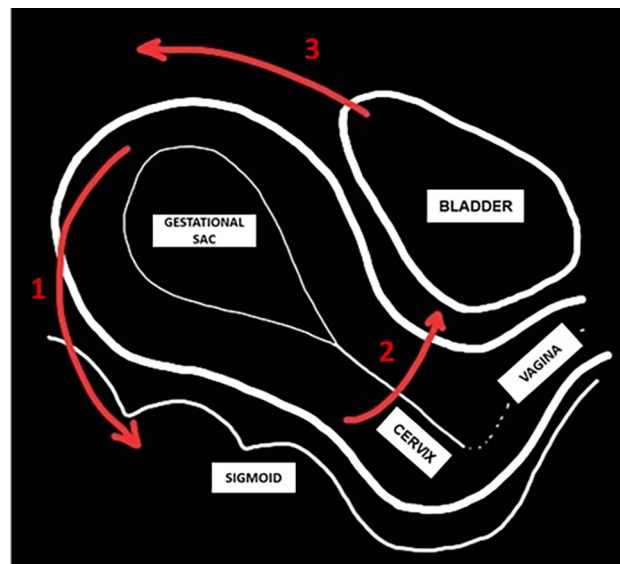


Figure 3 Diagram of a correct uterine disposition and the changes involved in the uterine incarceration process (red arrows). (1) The uterine fundus acquires a posterior position; (2) the cervix moves anteriorly; (3) the bladder is pulled superiorly and compressed.

OUTCOME AND FOLLOW-UP

The bladder catheter was removed at 24 weeks of gestation when an abdominal ultrasound scan showed that the uterus was positioned above the promontory. At this time, the patient was able to void normally. The patient's symptoms did not recur and the following ultrasound examinations confirmed that the uterus reassumed the correct polarity. There were no other complications throughout pregnancy and a healthy female infant (3570 g, 50 cm, Apgar 9/10/10) was successfully delivered by vaginal birth at 38 weeks of gestation. No further complications took place in the postpartum period. At 6 weeks post partum, the pelvic floor ultrasound was performed and it showed a retroverted uterus without signs of pelvic prolapse or abnormalities of the anterior compartment.

DISCUSSION

The IGU condition is strongly correlated with a retroverted uterus. Sadath *et al* recommends bimanual examination or trans-abdominal sonography be performed at 16 weeks of gestation in patients with a retroverted uterus to assess the uterine position. If it remains in the same position, the risk of IGU becomes elevated.⁸

However, a diagnosis remains difficult due to the non-specificity of its symptoms.¹ Among these symptoms, urinary retention is the most relevant. This is due to the uterine cervix extreme dislocation which causes urethral compression, loss of the urethrovesical angle and anatomical distortion of the bladder (see figure 3).^{1 8 9 11 12}

In a pregnant patient presenting urinary retention, who also presents with associated risk factors, IGU should be considered.⁸ We present a case of a retroverted IGU which occurred without predisposing factors.

In addition to clinical symptoms and physical examination, imaging is useful.

Han *et al* mention that, after the year 2000, the ability to diagnose IGU was superior and benefited from pelvic examination combined with imaging methods.¹ Although there is

no recognised standard test for IGU, both ultrasound and MRI seem to be adequate modalities.^{6 7 12 13}

Our case investigation used abdominal and transvaginal ultrasound and introital assessment of the pelvic floor. An MRI was not performed because sonographic findings were sufficient for the diagnosis, therefore the initial case management would not have changed with MRI data.

Abdominal ultrasound shows an advantage over transvaginal sonography.¹ This approach allows a better characterisation of the cervix and its anatomical relationships with the vagina and the bladder.

In fact, it can be difficult to find correct localisation of the cervix on transvaginal sonography, if it is elongated and wedged behind the symphysis, as it was observed in our patient.^{1 12} Fernandes *et al* state that the anterior position of the cervix is the most consistent clinical and sonographic finding for IGU.¹²

In our case, the complementary pelvic floor assessment was helpful in identifying the cause of AUR. Additionally, the presenting authors consider that the pelvic floor evaluation after delivery can be useful in identifying and assessing possible contributors for IGU and to assess the likelihood of recurrence of this condition in subsequent pregnancies. The authors recommend that the pelvic floor assessment be carried out in all IGU cases.

In existing literature, there is controversy surrounding AUR treatment due to incarcerated uterus. As in the described case, it is recommended performing bladder catheterisation first to relieve acute symptoms before attempting uterine repositioning.^{3 12}

Both Zhuang *et al* and Newell *et al* propose a diagnostic and therapeutic algorithm for AUR in pregnancy, which includes bladder decompression with emergency catheterisation followed by pelvic examination and ultrasound or MRI. After identifying IGU as the reason for urinary retention, manual reduction is suggested as a first-line treatment.^{3 11} If the manoeuvre is successful, consolidation treatments should be done: knee–chest or Trendelenburg positions, use of pessary and antibiotics, if infection is presented.¹¹ If the manoeuvre fails, more invasive interventions are performed including colonoscopy-assisted repositioning, laparoscopy or laparotomy.^{3 11} Gardner *et al* also describe a novel approach to the reduction of an incarcerated uterus, which involves placing the patient in an ‘all-fours’ position, maternal relaxation and fundal pressure with manipulation of the uterus through the maternal abdomen.¹⁴

It is important to highlight that IGU, if left untreated, may result in severe complications based on the stage of pregnancy. In the first trimester, AUR and miscarriage are some examples. In the second and third trimesters, it can result in fetal death, uterine rupture, bladder rupture, uterine ischaemia, intrauterine growth retardation, premature labour and delivery, renal failure and sepsis. The postpartum period might also be complicated with venous thrombosis or pulmonary embolism.^{2 15}

Literature defends that management should be initiated in early pregnancy, starting from non-invasive to more invasive treatments and different therapeutic approaches according to gestational age.¹⁰ Sadath *et al* affirm that optimal timing to management of incarceration is between 16 and 20 weeks.⁸ On one hand, procedures to correct the uterine position should be carried out as soon as possible. On the other hand, IGU may be spontaneously resolved with uterine growth with advancing gestational age. Takami *et al* state that an IGU, although rarely, may be spontaneously resolved even in the third trimester.⁴ Tachibana *et al* retrospectively reviewed 14 IGU and concluded

that IGU spontaneously resolved after 16 gestational weeks in 78.5% of the cases.⁹

Manual reduction seems to be the first-line treatment in early pregnancy, to resolve IGU.⁸

Kim *et al* mentioned that it is better to consider correcting IGU with passive or manual reduction before 20 weeks of gestation. If this fails, colonoscopy can be used as a subsequent management method. After that gestational age, due to enlarged uterus, the pelvic space is inadequate for such manoeuvres. If incarceration maintains, laparotomy is the final option and most of the cases were performed in the second trimester.¹⁰

If IGU still manifests in the third trimester, vaginal delivery is contraindicated and, at 36 weeks, a caesarean section with reduction of the incarcerated uterus is recommended. A detailed study of the anatomy of the pelvic structures is mandatory in planning the best surgical approach to the gravid uterus.⁸ In our case, there was a re-establishment of the correct anatomy during the second trimester therefore vaginal delivery possible.

With this manuscript, the authors would like to indicate even when manual reduction fails, passive reduction manoeuvres, consisting of knee–chest position and intermittent or long-duration urinary catheterisation, may be an option before scaling to more invasive interventions. Although bladder catheterisation might have carried a small risk of bladder infection,⁵ the decision of antibiotic prophylaxis until the moment of the catheter removal at 24 weeks of gestation.

Summarising, AUR is a rare emergency occurring in pregnancy. The diagnosis of IGU is still difficult, since it is a condition which requires prompt recognition and treatment. If not diagnosed and consequently untreated, it has some risks of severe outcomes during pregnancy. The treatment decision must be individualised, weighing the risks and benefits between a conservative and a more invasive attitude.

Learning points

- ▶ Uterine incarceration is a rare and unexpected complication during pregnancy. It happens when a retroverted uterus becomes trapped in the pelvis between the sacral promontory and the symphysis pubis.
- ▶ Incarcerated gravid uterus (IGU) is a difficult diagnosis, and if it persists during pregnancy, it may lead to adverse maternal and fetal outcomes.
- ▶ Acute urinary retention is one of the complications associated with the incarceration of a retroverted gravid uterus. IGU presents with an anterior displacement of the cervix and the upper vagina which leads to anatomical and functional changes of the bladder and urethra.
- ▶ IGU diagnosis can be suspected by clinical history and physical examination. Imaging techniques, such as abdominal, transvaginal and pelvic floor ultrasound, are essential to confirm the diagnosis and to guide the repositioning manoeuvres.
- ▶ Optimal timing for IGU management is between 16 and 20 weeks. Spontaneous resolution may occur as the pregnancy progresses and the uterus grows. However, treatment options can include bladder catheterisation, and passive and manual repositioning manoeuvres. If this fails, more invasive interventions might be performed under sedation or regional.

Contributors All authors had an important role in gathering patient information, treating the data, writing and reviewing the final manuscript. MMorais—bibliographical research on the topic and selection of recent articles to use as a reference; division of tasks between the authors; writing and planning the

background; writing and planning the case presentation; writing and planning the discussion; writing the abstract and learning points; organising references; creating graphic representation present in the two figures of the article; and digital treatment of images inserted in the manuscript. MMoura—collection of the patient consent; review of all manuscript writing; and writing the abstract and learning points. AC—responsible for pregnancy surveillance and delivery; and review of all manuscript writing. YF—gynaecologist who performed all diagnostic ultrasounds, namely the pelvic floor assessments, and review of all manuscript writing. MMorais responded to the reviewers' comments and reformulated the manuscript. MMoura reviewed the English grammar and adjusted the article to the journal's rules. AC and YF corrected and approved the new version of the manuscript. MMorais responded to the editor's comments, reformulated the manuscript and created figure 3. MMoura, AC and YF corrected and approved the new version of the manuscript.

Funding The authors have not declared a specific grant for this research from any funding agency in the public, commercial or not-for-profit sectors.

Competing interests None declared.

Patient consent for publication Obtained.

Provenance and peer review Not commissioned; externally peer reviewed.

Open access This is an open access article distributed in accordance with the Creative Commons Attribution Non Commercial (CC BY-NC 4.0) license, which permits others to distribute, remix, adapt, build upon this work non-commercially, and license their derivative works on different terms, provided the original work is properly cited and the use is non-commercial. See: <http://creativecommons.org/licenses/by-nc/4.0/>.

Case reports provide a valuable learning resource for the scientific community and can indicate areas of interest for future research. They should not be used in isolation to guide treatment choices or public health policy.

ORCID iD

Mariana Morais <http://orcid.org/0000-0003-4712-4943>

REFERENCES

- 1 Han C, Wang C, Han L, *et al*. Incarceration of the gravid uterus: a case report and literature review. *BMC Pregnancy Childbirth* 2019;19:408.
- 2 Gibbons JM, Paley WB. The incarcerated gravid uterus. *Obstet Gynecol* 1969;33:842–5.
- 3 Newell SD, Crofts JF, Grant SR. The incarcerated gravid uterus: complications and lessons learned. *Obstet Gynecol* 2014;123:423–7.
- 4 Takami M, Hasegawa Y, Seki K, *et al*. Spontaneous reduction of an incarcerated gravid uterus in the third trimester. *Clin Case Rep* 2016;4:605–10.
- 5 Yang J-M, Huang W-C. Sonographic findings in acute urinary retention secondary to retroverted gravid uterus: pathophysiology and preventive measures. *Ultrasound Obstet Gynecol* 2004;23:490–5.
- 6 Lackey A, Dara P, Burkhardt C. Recurrent incarceration of the severely retroverted uterus with successful second-trimester reduction. *J Obstet Gynaecol* 2019;39:549–51.
- 7 Dierckx I, Delens F, Backaert T, *et al*. Case report: incarceration of the gravid uterus: a radiologic and obstetric challenge. *J Radiol Case Rep* 2014;8:28–36.
- 8 Sadath H, Carpenter R, Adam K. Uterine incarceration in a primigravid retroverted bicornuate uterus. *BMJ Case Rep* 2016;2016:bcr2016215245.
- 9 Tachibana D, Misugi T, Kitada K, *et al*. Incarcerated gravid uterus: spontaneous resolution is not rare. *Diagnostics* 2021;11:1544.
- 10 Kim YS, Kwon BS, Lee YJ. Clinical approach and management of uterine incarceration according to trimester of pregnancy: case report and literature review. *Taiwan J Obstet Gynecol* 2021;60:911–5.
- 11 Zhuang L, Wang X-Y, Sang Y, *et al*. Acute urinary retention in the first and second-trimester of pregnancy: three case reports. *World J Clin Cases* 2021;9:3130–9.
- 12 Fernandes DD, Sadow CA, Economy KE, *et al*. Sonographic and magnetic resonance imaging findings in uterine incarceration. *J Ultrasound Med* 2012;31:645–50.
- 13 Slama R, Barry M, McManus K, *et al*. Uterine incarceration: rare cause of urinary retention in healthy pregnant patients. *West J Emerg Med* 2015;16:790–2.
- 14 Gardner B, Kozakiewicz ML, Whitecar PW, *et al*. Novel approach to reduction of an incarcerated uterus. *Obstet Gynecol* 2018;132:1177–9.
- 15 Gardner CS, Jaffe TA, Hertzberg BS, *et al*. The incarcerated uterus: a review of MRI and ultrasound imaging appearances. *AJR Am J Roentgenol* 2013;201:223–9.

Copyright 2022 BMJ Publishing Group. All rights reserved. For permission to reuse any of this content visit <https://www.bmj.com/company/products-services/rights-and-licensing/permissions/>
BMJ Case Report Fellows may re-use this article for personal use and teaching without any further permission.

Become a Fellow of BMJ Case Reports today and you can:

- ▶ Submit as many cases as you like
- ▶ Enjoy fast sympathetic peer review and rapid publication of accepted articles
- ▶ Access all the published articles
- ▶ Re-use any of the published material for personal use and teaching without further permission

Customer Service

If you have any further queries about your subscription, please contact our customer services team on +44 (0) 207111 1105 or via email at support@bmj.com.

Visit casereports.bmj.com for more articles like this and to become a Fellow