

# Pegfilgrastim-induced large vessel vasculitis

Hiroaki Saito, Tsuyoshi Suda , Naoki Oishi, Eiki Matsushita

Internal Medicine, Kanazawa Municipal Hospital, Kanazawa, Ishikawa, Japan

**Correspondence to**  
Dr Tsuyoshi Suda;  
t.suda1112@gmail.com

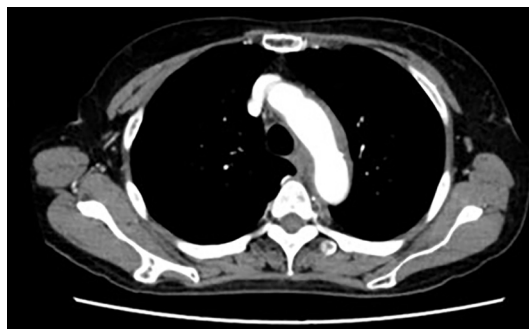
Accepted 20 May 2021

## DESCRIPTION

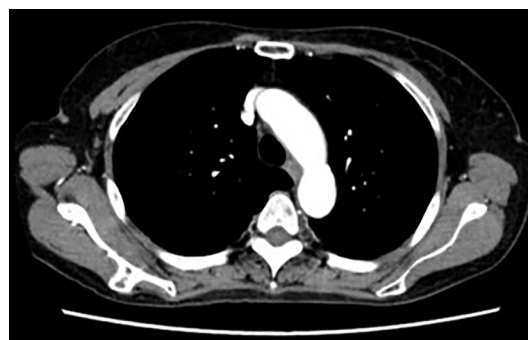
A 71-year-old woman underwent chemotherapy comprising gemcitabine and cisplatin for an unresectable intrahepatic cholangiocarcinoma. She received 3.6 mg of pegfilgrastim as prophylaxis for neutropenia and had no apparent problems immediately after its administration.

However, 1 week later, she developed general malaise, back pain and bilateral chest pain. She later developed high-grade fever, and visited our hospital 12 days after receiving pegfilgrastim.

Laboratory data revealed a white blood cell count and C-reactive protein (CRP) level of  $11.2 \times 10^9$  cells/L and 18.86 mg/dL, respectively. Infection was ruled out based on the physical and radiological findings and a negative blood culture. Due to chest and back pain, we performed contrast-enhanced CT (CECT), which, compared with prior imaging, revealed greater thickening of the aortic arch wall (figure 1). No obvious wall thickening was noted in any other vessel. Moreover, assays for autoantibodies were negative. Therefore, giant cell arteritis (GCA) and Takayasu arteritis (TAK) were considered as the possible causes of aortitis. However, there was no headache, temporal artery tenderness or visual disturbance, which are characteristics of GCA. Furthermore, the patient did not meet the American College of Rheumatology classification criteria for GCA. Polymyalgia rheumatica was also considered unlikely because there was no muscle pain or morning stiffness in the neck, shoulders, upper arms and thighs. Lastly, diminished peripheral pulses; blood pressure differences between the right and left arms; hypertension; and coldness, numbness or claudication of the limbs, which are characteristics of TAK, were absent. Therefore, considering the age of onset and clinical history, GCA and TAK were ruled out, and a diagnosis of pegfilgrastim-induced large vessel vasculitis was made.



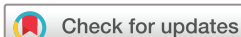**Figure 1** Contrast-enhanced CT scan clearly showing wall thickening of the aortic arch on admission.



**Figure 2** Contrast-enhanced CT after 3 weeks of prednisolone administration showing an improvement in the aortic wall thickening.

Conservative treatment involving pegfilgrastim withdrawal was considered, but the patient continued to have fever and chest pain for several days; therefore, treatment with prednisolone was started. We administered 30 mg/day of prednisolone orally (0.6 mg/kg/day; patient body weight: 52 kg). The patient's chest and back pain and fever quickly subsided after prednisolone administration. Thereafter, prednisolone was tapered gradually. After 3 weeks of prednisolone therapy, CECT showed reduction in aortic wall thickening (figure 2). Blood tests performed before prednisolone treatment revealed that the interleukin (IL)-6 level was high at 70.7 pg/mL; however, this decreased to 1.8 pg/mL after 3 weeks of prednisolone therapy.

Pegfilgrastim-associated aortitis is very rare; its incidence in patients with breast cancer treated by chemotherapy including pegfilgrastim is 0.3%.<sup>1</sup> However, severe side effects, such as aortic dissection, have been reported and clinicians should be aware of this.<sup>2</sup> In previous reports, most cases presented with high-grade fever and high CRP levels, and CT, MRI and positron emission tomography were used for diagnosis.<sup>3</sup> These imaging modalities play a major role in successful diagnosis and should be performed as early as possible when aortitis is suspected.<sup>4</sup> When infections or autoimmune diseases are ruled out, as in this case, patients should be thoroughly evaluated for aortitis and imaging studies should be performed. Furthermore, appropriate treatment with steroids should be started. Although the pathogenesis of pegfilgrastim-associated aortitis is presently unclear, it has been reported that the granulocyte colony-stimulating factor activates and mobilises immune mediators, such as IL-6, which may lead to drug-induced aortitis.<sup>5</sup> However, only few reports are available, and further investigations are required.



© BMJ Publishing Group Limited 2021. No commercial re-use. See rights and permissions. Published by BMJ.

**To cite:** Saito H, Suda T, Oishi N, *et al.* *BMJ Case Rep* 2021;**14**:e243757. doi:10.1136/bcr-2021-243757

## Learning points

- Large vessel vasculitis is a very rare side effect of pegfilgrastim and is often associated with high fever and high C-reactive protein levels; therefore, it is important to rule out infections or other autoimmune diseases.
- As activation of autoimmunity is believed to be one of the aetiological factors, steroids are used for the treatment of pegfilgrastim-induced large vessel vasculitis, as they improve symptoms and decrease blood interleukin-6 levels.

**Contributors** HS cared for the patient, edited the manuscript and prepared the figures. TS cared for the patient, edited the manuscript and obtained the written informed consent from the patient. NO and EM edited the manuscript and gave useful discussions.

**Funding** The authors have not declared a specific grant for this research from any funding agency in the public, commercial or not-for-profit sectors.

**Competing interests** None declared.

**Patient consent for publication** Obtained.

**Provenance and peer review** Not commissioned; externally peer reviewed.

## ORCID iD

Tsuyoshi Suda <http://orcid.org/0000-0001-9608-0444>

## REFERENCES

- 1 Lee SY, Kim EK, Kim J-Y, *et al*. The incidence and clinical features of PEGylated filgrastim-induced acute aortitis in patients with breast cancer. *Sci Rep* 2020;10:18647.
- 2 Sato Y, Kaji S, Ueda H, *et al*. Thoracic aortitis and aortic dissection following pegfilgrastim administration. *Eur J Cardiothorac Surg* 2017;52:993–4.
- 3 Hoshina H, Takei H. Granulocyte-Colony stimulating factor-associated aortitis in a woman with advanced breast cancer: a case report and review of the literature. *BMC Cancer* 2019;19:1217.
- 4 Taimen K, Heino S, Kohonen I, *et al*. Granulocyte colony-stimulating factor- and chemotherapy-induced large-vessel vasculitis: six patient cases and a systematic literature review. *Rheumatol Adv Pract* 2020;4:rkaa004.
- 5 Miller EB, Grosu R, Landau Z. Isolated abdominal aortitis following administration of granulocyte colony stimulating factor (G-CSF). *Clin Rheumatol* 2016;35:1655–7.

Copyright 2021 BMJ Publishing Group. All rights reserved. For permission to reuse any of this content visit <https://www.bmj.com/company/products-services/rights-and-licensing/permissions/>  
BMJ Case Report Fellows may re-use this article for personal use and teaching without any further permission.

Become a Fellow of BMJ Case Reports today and you can:

- Submit as many cases as you like
- Enjoy fast sympathetic peer review and rapid publication of accepted articles
- Access all the published articles
- Re-use any of the published material for personal use and teaching without further permission

## Customer Service

If you have any further queries about your subscription, please contact our customer services team on +44 (0) 207111 1105 or via email at [support@bmj.com](mailto:support@bmj.com).

Visit [casereports.bmj.com](http://casereports.bmj.com) for more articles like this and to become a Fellow